

Hepatoprotective effects of *Nigella Sativa* oil against acrylamide-induced liver injury in rats

Durmuş HATİPOĞLU^{1,a,✉}, Mehmet ÖZSAN^{2,b}, Hasan Hüseyin DÖNMEZ^{2,c}, Nurcan DÖNMEZ^{1,d}

¹Selcuk University, Faculty of Veterinary Medicine, Department of Physiology, 42130, Konya, Türkiye; ²Bartın University, Faculty of Engineering, Architecture and Design, 74110, Bartın, Türkiye; ³Selcuk University, Faculty of Veterinary Medicine, Department of Histology and Embryology, 42130, Konya, Türkiye

^aORCID: 0000-0003-3790-7821; ^bORCID: 0000-0001-9546-3478; ^cORCID: 0000-0003-4664-8489; ^dORCID: 0000-0003-4271-598X

ARTICLE INFO

Article History

Received : 31.03.2022

Accepted : 19.08.2022

DOI: 10.33988/auvfd. 1096306

Keywords

Acrylamide

Cytokines

Hepatotoxicity

Nigella sativa

Oxidative stress

✉Corresponding author

drhatip@selcuk.edu.tr

How to cite this article: Hatipoğlu D, Özsan M, Dönmez HH, Dönmez N (2023): Hepatoprotective Effects of *Nigella Sativa* Oil against Acrylamide-induced Liver Injury in Rats. Ankara Univ Vet Fak Derg, 70 (4), 419-426. DOI: 10.33988/auvfd. 1096306.

ABSTRACT

Acrylamide (AA) is a heat-induced carcinogen founds in some foods due to cooking or other thermal processes. This study was designed to investigate the possible protective efficacy of *Nigella sativa* essential oil against acrylamide-induced liver toxicity. Four groups of 32 male Wistar albino rats were formed. The control group was fed ad libitum. Acrylamide was administered to the rats in Group AA at a daily dose of 40 mg/kg by gavage. *Nigella sativa* essential oil was administered intraperitoneally at a dose of 10mg/kg to the rats in Group NS. In Group AA+NS, daily applications of acrylamide and *Nigella sativa* essential oil were applied simultaneously as mentioned above. The trial period lasted 15 days. While acrylamide statistically increased MDA levels in liver tissue (P<0.05), (146.13 %) and decreased GSH and SOD activity statistically (P<0.05), (55.28% and 40.46%). In addition, liver proinflammatory cytokine levels increased due to acrylamide administration (P<0.05), [TNF- α (78.17%), IL-6 (76.08%)], anti-inflammatory cytokine levels (P<0.05), [IL-10 (61.16%)] decreased. Co-administration of *Nigella sativa* essential oil with acrylamide significantly reduced oxidative stress and pro-inflammatory cytokine levels in liver tissues (P<0.05). In conclusion, our findings highlighted the potential therapeutic role of *Nigella sativa* essential oil in preventing acrylamide-induced hepatotoxicity.

Introduction

Acrylamide (AA) is a white solid powder, easily soluble in water, ethanol, and other solvents. It is widely used in the water treatment industry, textile industry, and cosmetics production (46). Consumption of high-temperature-cooked carbohydrate-rich foods is recognized as another major route of AA exposure (29). The level of AA found in fried and baked foods such as french fries (500 μ g/kg) and potato chips (750 μ g/kg) is reported to be more than 500 times the maximum allowable limit in drinking water determined by the World Health Organization (WHO) (38). Researchers note that the AA level is quite high in bread, biscuits, and coffee (46). Although the ways of exposure to AA in daily life are diverse, the main sources are food and drinking water. AA enters the body through the skin, digestive system, and

respiration, and can be rapidly distributed to all tissues and blood in the body, as it has strong tissue permeability (34,37).

AA decreases glutathione (GSH) and level superoxide dismutase (SOD) activity and significantly increases malondialdehyde (MDA) levels (33, 39). This imbalance between the increase in reactive oxygen species (ROS) and the antioxidant defense system increases oxidative stress in various tissues, especially in the liver, brain, and kidney (24). Increased oxidative stress leads to, genotoxicity reproductive system toxicity, neurotoxicity, carcinogenicity, and hepatotoxicity (17, 45). Also, it was reported that the production of inflammatory cytokines such as tumor necrosis factor- α (TNF- α), interleukin-6 (IL-6) and interleukin-1 β (IL-1 β) increase after AA intoxication (41). It was reported that AA intoxication

may have effects on the liver (9). AA is catalyzed in the liver via cytochrome P450 2E1 (CYP2E1) and metabolized to glycidamide (GA), a highly toxic substance for the organism (19). Besides, AA conjugates with GSH to be excreted in the urine as an alternative route in the liver (15). Although the metabolism of AA in the liver has been well defined, its hepatotoxicity has not been adequately clarified. There is also a growing concern about its effects on human and animal health since exposure to AA is both relatively easy in daily life and can be rapidly distributed throughout the organism.

Using *in vitro* and *in vivo* models, the researchers focused on finding protective compounds to reduce the toxic effects of AA. Therefore, some well-known antioxidants such as curcumin, crocin, linalool, and chrysin have been reported to be beneficial against the toxic effects of AA (20). *Nigella sativa* essential oil, (NS) is widely performed as a preservative and food additive as well as various diseases all over the world (26). NS, generally known as black seed or black cumin, has traditionally been used as a food preservative, additive, or applied as spice (6). According to the findings obtained from the studies carried out NS has antioxidative, anti-inflammatory, antifungal, anticonvulsant, immunomodulator, antinociceptive, antiallergic, antibacterial, antiviral, antidiabetic, antitumor, anti-hepato-nephrotoxic and neuroprotective effects (7, 43, 48).

In this context, the antioxidant and immunomodulatory effects of NS, which is claimed to have positive effects on many different diseases and is widely utilised as a spice, on the liver of rats with AA toxicity were investigated.

Materials and Methods

Chemicals and other reagents: AA was obtained from Sigma Chemical Company (St. Louis, Mo, USA). *Nigella sativa* L. was supplied by Botallife (Isparta, Türkiye). Malondialdehyde (MDA), glutathione (GSH, Cat. No: E1101Ra), superoxide dismutase (SOD) enzyme-linked immunosorbent assay (ELISA) kits were purchased from Bioassay Technology Laboratory (Shanghai, China). Tumour necrosis factor- α (TNF- α , Cat. No: ERA57RB), interleukin-1 beta (IL-1 β , Cat. No: BMS630), interleukin-6 (IL-6, Cat. No: ERA32RB) and interleukin 10 (IL-10, Cat. No: ERA24RB) ELISA kits were obtained from Thermo Fisher Scientific Inc. (Waltham, Massachusetts, USA).

Animals: The Selçuk University Experimental Medicine Research and Application Center Ethics Committee approved the animal handling and study protocol as ethical (Approval No. 2020-29). Thirty-two adults male Wistar Albino rats weighing 240 ± 20 g were obtained from Selçuk University Experimental Medicine Research

and Application Center. All rats were kept in a well-ventilated room with 12 hours of light/12 hours of natural light/dark cycle under standardized housing conditions at constant temperature (25 ± 2 °C) and humidity ($45 \pm 5\%$). During the study, commercial pellet diet and water were given *ad libitum*.

Animal groups and treatment schedule: In Control group, rats were exposed to free access to food and water; AA group rats were subjected to AA was dissolved in distilled water and animals gavaged 40 mg/kg /bw. one a day for fifteen consecutive days, according to Tabeshpour et al. (43); Rats including Ns group were administered NS 10mg/kg/bw. one a day for fifteen consecutive days, according to Abdullah et al. (4); and AA+NS group, rats co-administrated with AA and NS one a day for fifteen consecutive days. AA was administered orally by gavage, while NS administration was performed intraperitoneally. Body weight (bw) was measured baseline and after treatment weekly. All animals were sacrificed by servical dislocations under thiopental sodium anesthesia (40 mg/kg, i.p.) and tissue samples were taken after 24 h from the last application. Tissue samples were stored at -80 °C until spectrophotometric analysis. Some of the tissues were stored in Baker's formaldehyde-calcium solution until histopathological analysis.

Tissue sampling and homogenates: The liver was quickly removed, weighed, and cleaned with a cold saline solution. Tissues were chopped and homogenized (10% w/v) separately in a Potter-Elvehjem homogenizer in ice-cold sodium, potassium phosphate buffer (0.01 M, pH 7.4) containing 1.15 percent KCl. Tissue homogenates were then centrifuged at 5000 rpm for 10 minutes at 4 °C, and aliquots of supernatant were separated and quickly stored at 20 °C until further usage to test lipid peroxidation, antioxidant, and cytokine parameters (21). All reagents used were of the highest commercially available quality.

Evaluation of oxidative/antioxidant indices: Tissue oxidative stress and antioxidant indicators were assessed. As Ohkawa et al. (36), described, we measured the malondialdehyde (MDA, nmol/mg) level in liver homogenates to determine lipid peroxidation (36). Reduced glutathione (GSH, nmol/mg), an antioxidant marker, was examined as previously reported Breutler (11). The activities of antioxidant enzymes, superoxide dismutase (SOD, nmol/mg), was evaluated as stated by Nishikimi et al. (35).

Evaluation of cytokines levels: In tissue samples, pro-inflammatory (TNF- α , IL-6, IL-1 β) and anti-inflammatory (IL-10) cytokines were quantified using commercial

ELISA kits. TNF- α , IL-6, IL-1 β , and IL-10 (Pg/ml) levels were measured with anti-rat ELISA kits according to the manufacturer's instructions as mentioned above (47).

Histopathological investigation: Liver tissue samples were fixed in Baker's formaldehyde-calcium solution at +4 °C in the dark for at least 16 h. From each fixed liver sample, to estimate percentage volume of fat in the liver cells, 12-micrometer cross-sections were cut and stained with oil Red O. The sections were examined under the light microscope (Leica DM2500, Switzerland). According to the degree of hepatic lipidosis was classified as none (0%), mild (< 20%), moderate (20-40%) and severe (> 40%) (13).

Statistical Analysis: The SPSS 20.00 package program was used to conduct a statistical analysis of the data gathered at the study's end and determine the significance of the differences between groups. Analytical methods were preferred to analyze variables for normal distribution. All variables were reported as means standard error. The groups were compared using a one-way ANOVA test. Following the determination of variance homogeneity, in cases where the p-value was less than 0.05, pairwise post hoc comparisons (Tukey) were employed to test the significance of the groups, and Duncan's Multiple Range test was utilized in the analysis of variance.

Results

Oxidative/antioxidant indices following AA and/or NS treatment: AA exposure led to a significant increase in

MDA content ($P < 0.05$) and a significant decrease in GSH and SOD activities ($P < 0.05$) in liver samples compared to the control group. Meanwhile, the AA+NS group showed a significant increase in GSH and SOD activities compared to the AA group ($P < 0.05$), while the MDA level demonstrated a statistically significant decrease ($P < 0.05$). Besides, NS-treated rats had non-significant and similar values in oxidative stress/antioxidant parameters compared to the control group ($P > 0.05$) (Figure 1).

Cytokine levels indices following AA and/or NS treatment: AA-induced a series of inflammatory changes that mediated liver injury in this study. TNF- α , IL-1 β , and IL-6 levels were significantly higher in the AA group compared to the control group ($P < 0.05$). However, overproduction the levels of IL-1 β in the AA+NS group significantly inhibited compared with the AA-induced group ($P < 0.05$), but there was no significant difference in TNF- α and IL-6 levels ($P > 0.05$). While AA administration caused a significant decrease in IL-10 level differing from the control group. ($P < 0.05$), the level of this cytokine in the AA+NS group showed a statistically significant increase compared to the AA group ($P < 0.05$). Also, rats treated with NS had similar values in cytokine parameters compared to the control group ($P > 0.05$) (Figure 2).

Steatosis findings following AA and/or NS treatment: Histopathologically, no signs of steatosis were found in oil red-o staining performed to determine the fatty liver caused by acrylamide. Similar findings were also observed in the C, NS, and AA+NS groups (Figure 3).

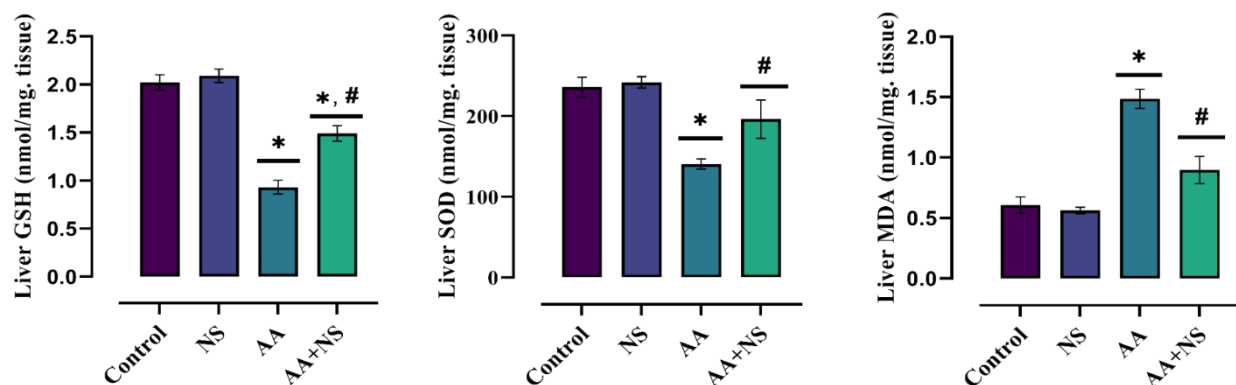


Figure 1. Results of *Nigella sativa* on AA-induced liver oxidative stress and antioxidant levels (Values are expressed as mean \pm SEM). Different symbols in the columns show a statistical difference (* indicates significant difference ($P < 0.05$) when compared with the control group, # indicates significant difference ($P < 0.05$) when compared with the acrylamide group). (NS; *Nigella sativa* group; AA; Acrylamide group; AA+NS; Acrylamide+*Nigella sativa* group).

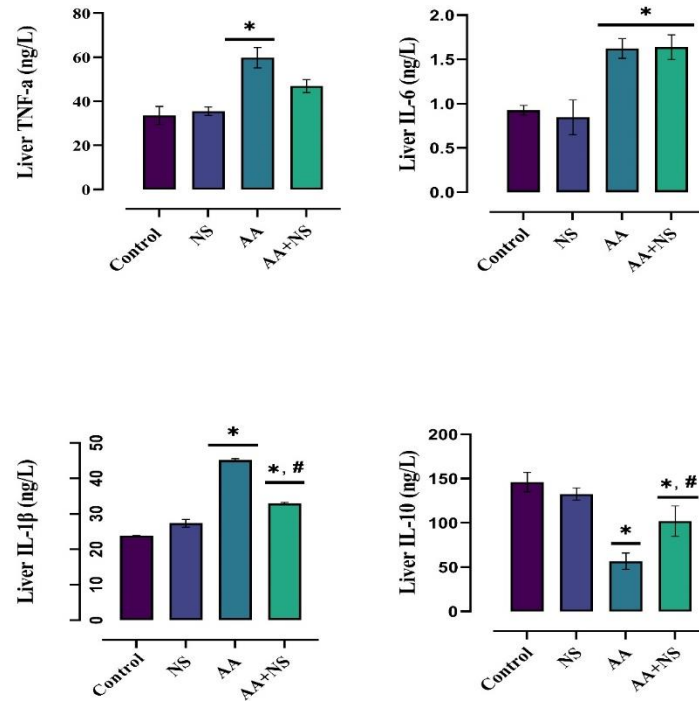


Figure 2. Results of *Nigella sativa* on AA-induced liver cytokine levels (Values are expressed as mean \pm SEM).

Different symbols in the columns show a statistical difference (* indicates significant difference ($P < 0.05$) when compared with the control group, # indicates significant difference ($P < 0.05$) when compared with the acrylamide group). (NS; *Nigella sativa* group; AA; Acrylamide group; AA+NS; Acrylamide+*Nigella sativa* group).

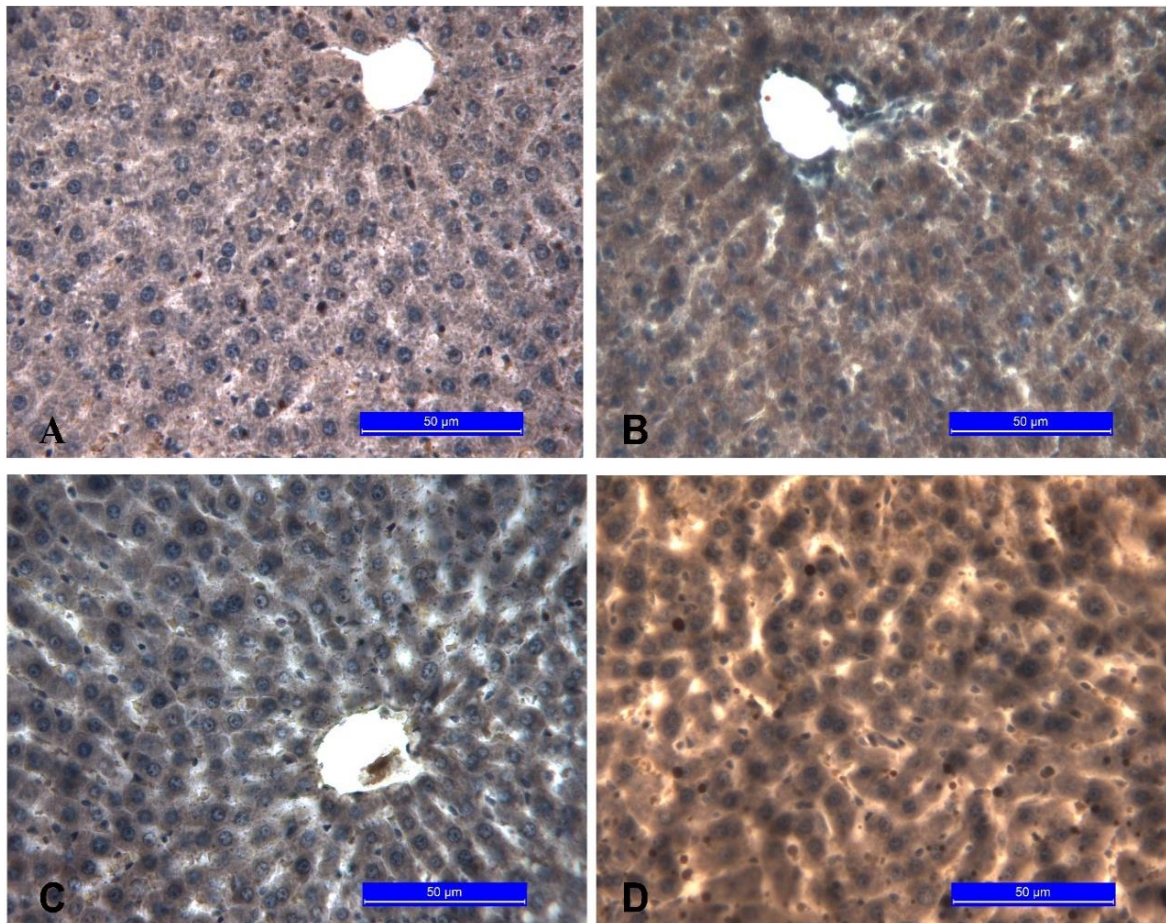


Figure 3. Results of *Nigella Sativa* on AA-induced liver steatosis findings.

A. Control group, B. NS group, C. AA group, D. AA+NS group.

Discussion and Conclusion

AA, classified as Group 2A (possibly carcinogenic to humans) by the International Agency for Research on Cancer, is a process contaminant formed as a result of heat treatment, especially in foods high in reducing sugar and asparagine (23). This contaminant, which is detected at different levels in foods that are frequently consumed in the daily diet, has been the focus of attention of many food and health authorities due to its known harmful potential health effects. Both the US National Toxicology Program and the Joint Food and Agriculture Organization/World Health Organization Expert Committee on Food Additives JECFA consider AA as a human health problem. AA has a highly toxic effect as it can spread easily to tissues after ingestion (10).

ROS, which is produced as a physiological product of cellular metabolism, leads to oxidative stress, which is considered pathological, in abnormal conditions such as toxicity (25). Exposure of animals or humans to a xenobiotic or hazardous substance such as AA gives rise to an imbalance in ROS production and neutralization (1).

As shown in Figure 1, while AA significantly increased MDA, a lipid peroxidation product, in liver tissues, it led to a decrease in antioxidant capacities such as GSH and SOD. This change in MDA, GSH, and SOD levels has been accepted as an indicator of the occurrence of oxidative stress induction and cell membrane lipid damage resulting in AA-induced hepatocyte necrosis. The findings we obtained are similar to previous studies (5, 12). It was reported that AA causes the formation of free radicals, disrupts the antioxidant defense system, and ultimately leads to oxidative stress and carcinogenesis (40). Non-physiological changes found in the levels of oxidative stress and antioxidant defense system are accepted as an indicator of AA-induced hepatotoxicity (5). Biotransformation to glycidamide (GA) (44), which causes mutagenicity and carcinogenicity in the liver via CYP2E1 of AA, is considered a key process in the carcinogenesis of this toxic substance (41). Both AA and GA are covalently bound to GSH for subsequent urinary excretion and are capable of forming AA-GSH and GA-GSH conjugates. GSH conjugates are an important detoxification pathway against ROS resulting from the toxic effect of AA (32). After the GSH pools are depleted, ROSs react with lipids in the cell membrane (42). As a result, these reactive molecules, which cause lipid peroxidation, leading to an increase in lipid peroxidation products such as MDA (36). The body's enzymatic (such as SOD, CAT, and GPx) or non-enzymatic (such as GSH, selenium, vitamin C, vitamin E) antioxidant systems are responsible for scavenging these ROS and protecting DNA and macromolecules from degradation (8). In conclusion, we thought that AA toxication caused liver

damage by decreasing the amount of GSH and SOD and inducing the synthesizing of MDA.

NS, which shows biological activity through its active ingredient thymoquinone, has a radical scavenging (anti-oxidative) effect (16). In this study, it was concluded that NS could protect against AA-induced toxicity by significantly reducing the level of lipid peroxidation product (MDA) and increasing antioxidant enzyme levels (GSH, SOD) (Figure 1). These findings comply with previous studies showing the hepatoprotective efficacy of NS as a result of exposure to different toxic substances (1). As a matter of fact, Abdel-Daim and Ghazy (2) reported that significant changes in serum biochemical markers, tissue antioxidant, and lipid peroxidation products in animals treated with oxytetracycline significantly inhibited hepato-lipid peroxidation when treated with NS (2). Similarly, Abdel-Wahab (3) stated that thymoquinone (TQ) administration greatly normalized suppressed enzymatic and non-enzymatic antioxidant levels and reduced hepatic biomarkers and lipid peroxidation (3). Besides, studies have revealed that thymohydroquinone, the reduced form of TQ, shows strong antioxidant properties by returning electrons to hydroxyl radicals (OH) and superoxide radicals, which attack polyunsaturated fatty acids in the cell membrane (27). Based on these findings, we concluded that NS plays a key role in cellular protective mechanisms and exerts hepatoprotective effects by preventing or reducing tissue destruction caused by AA-induced ROS, increasing the level of GSH and SOD, and preventing the formation of lipid peroxidation products.

Cells in the liver can produce cytokines, which act paracrine or autocrine, leading to more cytokine production and amplification of the inflammatory response (30). However, the main source of this inflammatory response in the liver is believed to be Kupffer cells (14). Toxic damage by xenobiotics leads to the secretion of different mediators, including cytokines (TNF- α , IL-1 β , and IL-6). The inability of the organism to compensate for the over-release of reactive oxygen species (depletion of enzymatic and non-enzymatic antioxidants) forms the basis of oxidative stress that gives rise to liver damage (30). The present study shows that AA, an industrial xenobiotic, increases the levels of liver IL-6, IL-1 β , and TNF- α proinflammatory cytokines, and decreases the anti-inflammatory cytokine IL-10 (Figure 2). The data we obtained comply with previous studies stating that this toxic substance stimulates inflammatory cells and causes an increase in inflammatory response by releasing cytokines (12, 30). In the current study, we concluded that the increase in TNF- α , IL1 β , and IL-6 levels in the liver as a result of AA toxicity may be associated with severe oxidative damage due to decreased

levels of enzymatic and non-enzymatic antioxidant defense system members (GSH and SOD) and increased MDA level.

Concomitant NS treatment with AA significantly decreased liver IL-1 β levels, while this decrease in TNF- α level, although not significant, tended to decrease (Figure 2). The reason for this is thought to suppress the inflammatory process by neutralizing the oxidative stress that causes liver damage, thanks to the antioxidative and anti-inflammatory effects of NS (48). Our findings are also consistent with another study stating that thymiconicone, the main component of NS, decreased the activities of inflammatory markers such as TNF- α and IL-1 β in rats exposed to experimental AA toxicity (1). Also, the increase in IL-10 levels caused by NS treatment was remarkable. (Figure 2) The positive changes in pro-inflammatory and anti-inflammatory cytokine levels as a result of NS treatment reveal that this herbal agent is a good immunomodulator. Indeed, the use of NS has been shown to have immunomodulatory effects in various inflammatory diseases (48).

The liver is the primary organ for drug and environmental agent metabolism. Increased fatty acid production, mitochondrial dysfunction, modification of nuclear receptor activation, insulin resistance, and reduced lipid excretion have all been linked to the development of hepatic steatosis after exposure to some of these drugs and environmental agents (22). Many industrial chemicals, including halogenated hydrocarbons, volatile organic mixtures, pesticides, and certain nitro organic compounds, have been related to toxicant-associated fatty liver disease and toxicant-associated steatohepatitis (22). Chronic amiodarone exposure has been associated with hepatic steatosis in individuals due to mitochondrial dysfunction and lipid oxidation inhibition (28). Long-term usage of the antiepileptic medication valproic acid has also been linked to fatty liver disease (18). Other drugs, such as tamoxifen, tetracycline, methotrexate, and corticosteroids, have also resulted in human steatosis has been associated with steatosis in the liver (31). No evidence of hepatic steatosis was found between the groups in the present study (Figure 3). Hepatic steatosis, which is closely related to chronic exposure to toxic and pharmaceutical substances, was not thought to occur due to the short duration of the current study.

In conclusion, this study revealed that AA intoxication leads to lipid peroxidation, oxidative stress, and liver damage through a severe inflammatory response. Besides, the present study also showed that intraperitoneally administered NS has a hepatoprotective effect by protecting the liver from AA-induced oxidative stress and pathological cytokine synthesis.

Financial Support

This research received no grant from any funding agency/sector.

Conflict of Interest

The authors declared that there is no conflict of interest.

Author Contributions

DH, MÖ and ND conceived and planned the experiments. DH and MÖ carried out the experiments. DH, MÖ and HHD contributed to sample preparation. DH, ND and HHD contributed to the interpretation of the results. DH took the lead in writing the manuscript. All authors provided critical feedback and helped shape the research, analysis and manuscript.

Data Availability Statement

The data supporting this study's findings are available from the corresponding author upon reasonable request.

Ethical Statement

This study was approved by the Selçuk University Experimental Medicine Research and Application Center Ethics Committee (2020-29).

Animal Welfare

The authors confirm that they have adhered to ARRIVE Guidelines to protect animals used for scientific purposes.

References

1. **Abdel-Daim MM, Abo El-Ela FI, Alshahrani FK, et al** (2020): *Protective effects of thymoquinone against acrylamide-induced liver, kidney and brain oxidative damage in rats*. Environ SciPollut Res, **27**, 37709-37717.
2. **Abdel-Daim MM, Ghazy EW** (2015): *Effects of Nigella sativa oil and ascorbic acid against oxytetracycline-induced hepato-renal toxicity in rabbits*. Iran J Basic Med Sci, **18**, 221-227.
3. **Abdel-Wahab WM** (2014): *Thymoquinone attenuates toxicity and oxidative stress induced by bisphenol A in liver of male rats*. Pak J Biol Sci, **17**, 1152-1160.
4. **Abduallah AM, Rashed AA, Gamaleldeen AK, et al** (2017): *The effect of nigella sativa extract (thymoquinone) on glucose insulin levels and body weight of induced diabetic female rats*. Am J Life Sci, **5**, 52-56.
5. **Al-Qahtani F, Arafah M, Sharma B, et al** (2017): *Effects of alpha lipoic acid on acrylamide-induced hepatotoxicity in rats*. Cell Mol Biol, **63**, 1-6.
6. **Ali BH, Blunden G** (2003): *Pharmacological and toxicological properties of Nigella sativa*. Phytother Res, **17**, 299-305.
7. **Ates MB, Ortatagli M, Oguz H, et al** (2022): *The ameliorative effects of Nigella sativa, thymoquinone, and bentonite against aflatoxicosis in broilers via AFAR and Nrf2 signalling pathways, and down-regulation of caspase-3*. Br Poult Sci, 1-8.

8. **Battin EE, Brumaghim JL** (2009): *Antioxidant activity of sulfur and selenium: a review of reactive oxygen species scavenging, glutathione peroxidase, and metal-binding antioxidant mechanisms.* Cell Biochem. Biophys, **55**, 1-23.
9. **Belhadj Benziane A, Dilmi Bouras A, Mezaini A, et al** (2019): *Effect of oral exposure to acrylamide on biochemical and hematologic parameters in Wistar rats.* Drug Chem Toxicol, **42**, 157-166.
10. **Besaratinia A, Pfeifer GP** (2007): *A review of mechanisms of acrylamide carcinogenicity.* Carcinogenesis, **28**, 519-528.
11. **Beutler E** (1963): *Improved method for the determination of blood glutathione.* J Lab Clin Med, **61**, 882-888.
12. **Bin-Jumah MN, Al-Huqail AA, Abdelnaeim N, et al** (2021): *Potential protective effects of Spirulina platensis on liver, kidney, and brain acrylamide toxicity in rats.* Environ Sci Pollut Res, **28**, 26653-26663.
13. **Civelek T, Sevinc M, Boydak M, et al** (2006): *Serum apolipoprotein B100 concentrations in dairy cows with left sided displaced abomasum.* Rev Med Vet, **157**, 361.
14. **Ding H, Peng R, Reed E, et al** (2003): *Effects of Kupffer cell inhibition on liver function and hepatocellular activity in mice.* Int J Mol Med, **12**, 549-557.
15. **Dixit R, Mukhtar H, Seth PK, et al** (1981): *Conjugation of acrylamide with glutathione catalysed by glutathione-S-transferases of rat liver and brain.* Biochem Pharmacol, **30**, 1739-1744.
16. **El-Dakhkhny M, Madi NJ, Lembert N, et al** (2002): *Nigella sativa oil, nigellone and derived thymoquinone inhibit synthesis of 5-lipoxygenase products in polymorphonuclear leukocytes from rats.* J Ethnopharmacol, **81**, 161-164.
17. **Erfan OS, Sonpol HMA, Abd El-kader M** (2021): *Protective effect of rapamycin against acrylamide-induced hepatotoxicity: The associations between autophagy, apoptosis, and necroptosis.* Anat Rec, **304**, 1984-1998.
18. **Farinelli E, Giampaoli D, Cenciarini A, et al** (2015): *Valproic acid and nonalcoholic fatty liver disease: A possible association?* World J Hepatol, **7**, 1251-1257.
19. **Ghanayem BI, Witt KL, Kissling GE, et al** (2005): *Absence of acrylamide-induced genotoxicity in CYP2E1-null mice: evidence consistent with a glycidamide-mediated effect.* Mutat Res, **578**, 284-297.
20. **Guo J, Cao X, Hu X, et al** (2020): *The anti-apoptotic, antioxidant and anti-inflammatory effects of curcumin on acrylamide-induced neurotoxicity in rats.* BMC Pharmacology and Toxicology, **21**, 62.
21. **Hamza RZ, Abd El-Azez AM, Hussien NA** (2015): *Evaluation of the antioxidant potential for different extracts of Al-taif pomegranate (Punica granatum L.) induced by atrazine and malathion pesticides in liver of male albino mice.* Int J Pharm Sci Res, **7**, 89-94.
22. **Heindel JJ, Blumberg B, Cave M, et al** (2017): *Metabolism disrupting chemicals and metabolic disorders.* Reprod Toxicol, **68**, 3-33.
23. **IARC** (1994): *Some industrial chemicals.* International Agency for Research on Cancer. "Some Industrial Chemicals." Monographs on the Evaluation of the Carcinogenic Risk of Chemicals to Humans 60 (1994). Monographs on the Evaluation of the Carcinogenic Risk of Chemicals to Humans, 60.
24. **Ibrahim MA, Ibrahim MD** (2019): *Acrylamid-induced hematotoxicity, oxidative stress, and DNA damage in liver, kidney, and brain of catfish (Clarias gariepinus).* Environ Toxicol, **35**, 300-308.
25. **Jakubczyk K, Dec K, Kalduńska J, et al** (2020): *Reactive oxygen species-sources, functions, oxidative damage.* Pol Merkur Lekarski, **48**, 124-127.
26. **Karimi Z, Mirza Alizadeh A, Ezzati Nazhad Dolatabadi J, et al** (2019): *Nigella sativa and its Derivatives as Food Toxicity Protectant Agents.* Adv Pharm Bull, **9**, 22-37.
27. **Khithier H, Sobhi W, Mosbah A, et al** (2018): *Prophylactic and curative effects of thymoquinone against CCL4-induced hepatotoxicity in rats.* Eur J Med Chem, 1-8.
28. **Kneeman JM, Misdraji J, Corey KE** (2011): *Secondary causes of nonalcoholic fatty liver disease.* Therap Adv Gastroenterol, **5**, 199-207.
29. **Kunnel SG, Subramanya S, Satapathy P, et al** (2019): *Acrylamide Induced Toxicity and the Propensity of Phytochemicals in Amelioration: A Review.* Cent Nerv Syst Agents Med Chem, **19**, 100-113.
30. **Lacour S, Gautier JC, Pallardy M, et al** (2005): *Cytokines as potential biomarkers of liver toxicity.* Cancer Biomark, **1**, 29-39.
31. **López-Riera M, Conde I, Tolosa L, et al** (2017): *New microRNA Biomarkers for Drug-Induced Steatosis and Their Potential to Predict the Contribution of Drugs to Non-alcoholic Fatty Liver Disease.* Front Pharmacol, **8**, 22-36.
32. **Luo YS, Long TY, Shen LC, et al** (2015): *Synthesis, characterization and analysis of the acrylamide- and glycidamide-glutathione conjugates.* Chem Biol Interact, **237**, 38-46.
33. **Mohamed Sadek K** (2012): *Antioxidant and immunostimulant effect of carica papaya linn. Aqueous extract in acrylamide intoxicated rats.* Acta Inform Med, **20**, 180-185.
34. **Mojska H, Gielecińska I, Cendrowski A** (2016): *Acrylamide content in cigarette mainstream smoke and estimation of exposure to acrylamide from tobacco smoke in Poland.* Ann Agric Environ Med, **23**, 456-461.
35. **Nishikimi M, Appaji Rao N, Yagi K** (1972): *The occurrence of superoxide anion in the reaction of reduced phenazine methosulfate and molecular oxygen.* Biochem Biophys Res Commun, **46**, 849-854.
36. **Ohkawa H, Ohishi N, Yagi K** (1979): *Assay for lipid peroxides in animal tissues by thiobarbituric acid reaction.* Anal Biochem, **95**, 351-358.
37. **Pyo MC, Shin HS, Jeon GY, et al** (2020): *Synergistic interaction of ochratoxin A and acrylamide toxins in human kidney and liver cells.* Biol Pharm Bull, **43**, 1346-1355.
38. **Rifai L, Saleh FA** (2020): *A Review on Acrylamide in Food: Occurrence, Toxicity, and Mitigation Strategies.* Int J Toxicol, **39**, 93-102.
39. **Salimi A, Hashemidanesh N, Seydi E, et al** (2021): *Restoration and stabilization of acrylamide-induced DNA, mitochondrial damages and oxidative stress by chrysin in human lymphocyte.* Expert Opin Drug Metab Toxicol, **17**, 857-865.
40. **Santhanasabapathy R, Vasudevan S, Anupriya K, et al** (2015): *Farnesol quells oxidative stress, reactive gliosis and inflammation during acrylamide-induced*

- neurotoxicity: Behavioral and biochemical evidence. *Neuroscience*, **308**, 212-227.
41. **Settels E, Bernauer U, Palavinskas R, et al** (2008): *Human CYP2E1 mediates the formation of glycidamide from acrylamide*. *Arch Toxicol*, **82**, 717-727.
42. **Suzuki N, Sawada K, Takahashi I, et al** (2020): *Association between polyunsaturated fatty acid and reactive oxygen species production of neutrophils in the general population*. *Nutrients*, **12**, 3222.
43. **Tabeshpour J, Mehri S, Abnous K, et al** (2020): *Role of Oxidative Stress, MAPKinase and Apoptosis Pathways in the Protective Effects of Thymoquinone Against Acrylamide-Induced Central Nervous System Toxicity in Rat*. *Neurochem Res*, **45**, 254-267.
44. **Thielen S, Baum M, Hoffmann M, et al** (2006): *Genotoxicity of glycidamide in comparison to (±)-anti-benzo[a]pyrene-7,8-dihydrodiol-9,10-epoxide and α -acetoxy-N-nitroso-diethanolamine in human blood and in mammalian V79-cells*. *Mol Nutr Food Res*, **50**, 430-436.
45. **Tyl RW, Friedman MA** (2003): *Effects of acrylamide on rodent reproductive performance*. *Reprod Toxicol*, **17**, 1-13.
46. **Vattem DA, Shetty K** (2003): *Acrylamide in food: a model for mechanism of formation and its reduction*. *Innov Food Sci Emerg Technol*, **4**, 331-338.
47. **Yousuf S, Atif F, Sayeed I, et al** (2013): *Post-stroke infections exacerbate ischemic brain injury in middle-aged rats: immunomodulation and neuroprotection by progesterone*. *Neuroscience*, **239**, 92-102.
48. **Zielińska M, Dereń K, Polak-Szczybyło E, et al** (2021): *The Role of Bioactive Compounds of Nigella sativa in Rheumatoid Arthritis Therapy-Current Reports*. *Nutrients*, **13**, 3369.

Publisher's Note

All claims expressed in this article are solely those of the authors and do not necessarily represent those of their affiliated organizations, or those of the publisher, the editors and the reviewers. Any product that may be evaluated in this article, or claim that may be made by its manufacturer, is not guaranteed or endorsed by the publisher.
